



Conservative Approach to Smile Design Using a Clear Aligner and Direct Composite Veneers

Malaligned, discolored teeth improved with more affordable, less invasive method

Emil Hawary, DDS, FAACD, FAGD, DICOI

Many adult patients who desire cosmetic enhancement of their malaligned dentition do not want to have traditional braces.^{1,2} A clear aligner such as the Invisalign® System (Align Technology, Inc., www.invisalign.com) is a technologically advanced approach to treating malocclusion and offers an esthetic alternative for patients who are reluctant to accept orthodontic treatment.^{1,2}

Invisalign can be a useful tool for limited movement of teeth/root positions to set up esthetic restorative treatment.³ In many cases, combining orthodontics with veneers provides a conservative esthetic outcome by avoiding aggressive tooth preparation.⁴

Laminate veneers have become popular as a less invasive and more conservative treatment to provide a more pleasing appearance of the anterior teeth. Veneering using ceramics requires more removal of tooth structure and is more expensive. Though improved properties of indirect composite restorations have provided an added advantage, they require a more invasive tooth preparation with two appointments and higher cost.⁵



**EMIL HAWARY, DDS,
FAACD, FAGD, DICOI**
Private Practice
Irvine, California

Direct composite resins represent an attractive restorative option for patients who desire minimally invasive treatment or cannot afford more costly indirect alternatives.^{6,7}

Through developments in composites, which are now equal to or better than some porcelain systems, enhanced optical properties and esthetics can be realized in direct restorations.⁸

“Invisalign can be useful for limited movement of teeth/root positions to set up esthetic restorative treatment.”

In the anterior region, it is important to produce restorations that not only mimic nature, but are undetectable from the surrounding natural dentition.⁹ Color matching is viewed as one of the most challenging tasks in esthetic dentistry¹⁰ because of the multidimensional properties of color and shape. The replication of natural polychromicity is the key to restoring natural esthetics and harmony.¹¹ This can be achieved through mastery of stratification, which creates restorations with both resin and ceramic materials that invisibly blend into the surrounding dentition.¹²

Stratification techniques have been used to achieve a light-composite-color relationship similar to natural tooth structure, and for the

anatomic reproduction of dentin and enamel tissues to the proper thickness and position.¹³

This article describes a step-by-step, procedural, multidisciplinary, and conservative approach for the predictable realization of esthetic anterior direct restorations.

Case Presentation

A 44-year-old female patient presented for cosmetic treatment. She was particularly bothered by the gaps between her incisors and the dark color of No. 10 (Figure 1 and Figure 2). She wanted a conservative way to close the gaps and mask the discolored tooth. She was also interested in achieving a more attractive feminine smile.

The clinical exam revealed that the patient had spacing between her upper incisors. She also had a leaking palatal amalgam filling on tooth No. 10 and old leaking amalgam fillings on some posterior teeth that required replacement. After analyzing the patient's study models, careful consideration was given to the midline and a smile design to achieve a symmetrical result.

The cosmetic analysis revealed that the patient's smile was not esthetically pleasing and violated a number of principles of the ideal smile design. The midline was canted and shifted towards the patient's right. The incisal plane and axial inclination of teeth Nos. 7 through 9 were also canted. There was spacing between upper incisors, and teeth Nos. 8 and 9 were rotated (Figure 3). The smile line was reversed, and tooth No. 10 was badly discolored.

Treatment Plan

In keeping with the patient's wishes and the clinical details of her case, it was recommended

that Invisalign be done first to allow for a more conservative veneer preparation, followed by direct resin veneers for resizing and reshaping teeth Nos. 6 through 11. Moving the teeth using the Invisalign appliance to close the gaps would result in a more symmetrical smile as well as smaller, more feminine teeth. Closing the gaps with veneers results in somewhat larger, more masculine teeth.

Treatment goals of the Invisalign appliance were to: correct the spacing and misalignment in the maxillary arch; correct the crowding in the mandibular arch; extrude teeth Nos. 8 and 9 to be leveled with Nos. 6 and 10; correct the reverse smile line; align the upper and lower midlines; and expand the premolars to correct the buccal corridor.

Invisalign® Treatment

Polyvinyl siloxane (PVS) impressions of the patient's teeth were obtained, as was a bite registration; they were sent to Align Technology along with copies of the full-mouth radiographs and intraoral and extraoral photography for the production of a series of aligners.

Six months through the Invisalign treatment, when the gaps were relatively closed and the incisors were symmetrically placed in relation to the midline (Figure 4 and Figure 5), a new smile analysis was performed. There was a significant improvement in teeth alignment, smile line, and buccal corridor. However, the patient's smile was still not esthetically pleasing. To achieve the feminine and uniform smile the patient desired, a pretreatment wax-up was completed, creating ideal morphology and arrangement of the teeth, and the midline was also corrected to eliminate the cant.

Two impressions of the wax-up were made with PVS putty material (RSVP™, Cosmedent, www.cosmedent.com). One impression was cut along the incisal edges to be used as a matrix to guide the lingual and incisal formation of the teeth and to create a backdrop onto which the composite resins could be layered. The other impression would be used to fabricate the mock-up temporaries. The wax-up model was duplicated in stone to create a vacuum-formed stent to be used as a preparation guide to ensure the preservation of as much tooth structure as possible.

Preparation

After anesthetizing the teeth, the amalgam fillings on the palatal surfaces of Nos. 10 and

7 were removed and replaced with composite restorations. To mask the black discoloration of tooth No. 10, a base of opaque dentin A was used first, followed by pink opaque.

Preparation of veneers was then initiated with a 770.10 bur (DENTSPLY Caulk, www.dentsply.com) using the pinhole prep guide (Copyplast, Scheu Dental Technology, www.greatlakesortho.com). Retraction cords (Ultradent, www.ultradent.com) were used to protect the gum during preparation and to help placing the finishing line slightly subgingivally.

Using PVS impression off the wax-up study casts and with the use of Luxatemp® shade A1 (DMG America, www.dmg-america.com), the provisional restorations were made, trimmed, polished, and cemented on the patient's teeth with clear Temp-Bond® (Kerr, www.kerrdental.com) to check the improvement of the patient's smile (Figure 6). The patient was dismissed and scheduled to return in few days for building up the chairside veneers.

Bonding and Layering for Resin Veneers

When the patient returned, she was happy with her new smile. The mock-up temporaries were separated so they could be removed one by one during the process of building the veneers, which was done one tooth at a time starting with No. 8 and followed by teeth Nos. 9, 7, 10, 6, and 11 consecutively. This technique offered better guidance for accurately creating shape, form, length, and axial inclination of veneers as well as midline position.

Shade A1 (progressive shade) was selected. The centrals were to be the brightest teeth and in order to achieve that, shade B1 was to be added at the incisal one third of the tooth. The laterals were totally built using A1 shade, and the canines were to be the richest in color by adding more A2 at the cervical one third to mimic the natural progression of shade.

After etching and bonding, the matrix was then positioned on the lingual aspect of the maxillary anterior teeth. The initial layer of composite shade A1 and B1 microhybrid (Renamel™, Cosmedent) was placed on tooth No. 8 on the lingual aspect. This initial layer created a lingual shell to act as a support for the rest of the restorations. Clear matrix strips (3M ESPE, www.3mespe.com) were used at this point to separate the teeth.

After a 20-second cure, a second layer of microfill A1 and B1 was sculpted to mimic the mamelons and then cured for 20 seconds. A very small amount of diluted blue tint

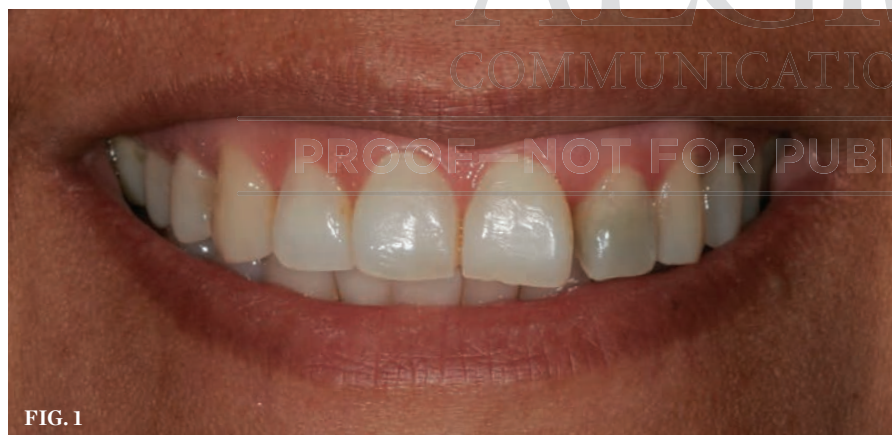

FIG. 1

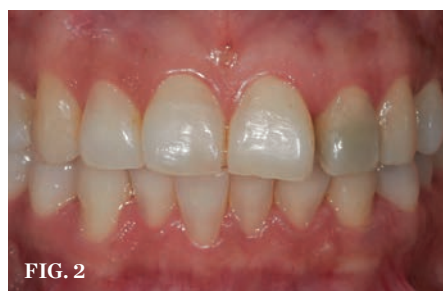

FIG. 2

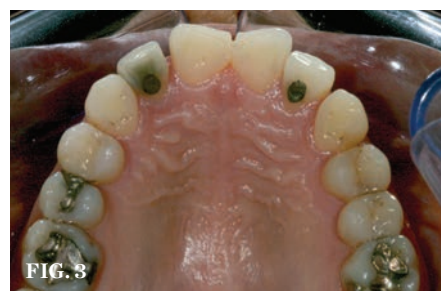


FIG. 3

(1.) Pretreatment full smile. (2.) Pretreatment retracted frontal view. (3.) Pretreatment occlusal view, maxilla.

Restorative

(Renamel Creative Color Composite Stains, Cosmedent) was painted onto the incisal edge of each mamelon and then light cured. A small amount of white opaque tint was placed along the internal aspect of the incisal bevel to create an internal halo effect. Some maverick colors, including ochre (Kolor Plus Stain Kit, Kerr), were also added to mimic her natural dentition. In the incisal one third, room was left to add light incisal microfill. This was sculpted with IPC carver (Cosmedent) and #1 and #2 brushes to create slight developmental depressions. The composite was contoured, and when visual symmetry was attained, it was cured for 60 seconds with an anti-oxidizing agent. Long flame-shaped, red-stripped diamonds were used to create the shape of the central incisor.

Adhesion was accomplished similarly with tooth No. 9. The two centrals were grossly finished and measured to ensure that identical contralateral shapes existed. The described bonding protocol used on teeth Nos. 8 and 9 was again performed on Nos. 6, 7, 10, and 11 using A1 shade. To mask the discoloration of No. 10, the tooth was prepared more and opaqued using pink opaque (Cosmedent). It was then layered with dentin opaque shade A1, followed by the same layering technique using shade A1.

Finishing

Occlusion was adjusted in centric occlusion and eccentric excursions prior to the final

finishing and polishing. Finishing was generated with blue and pink points and cups (Cosmedent) and coarse, medium, fine, and super-fine finishing and polishing strips and discs (Sof-Lex™, 3M ESPE) with polishing paste (Enamelize™, Cosmedent). Centrals were made slightly longer to create a more convex and pleasing smile line.

Clinical check confirmed contralateral symmetry, shade matching, and flawless margins between the patient's natural tooth and composite restorations. The teeth gave off a luminescent, lifelike appearance, and demonstrated undetectable restorations. The patient was happy with her pleasing new smile (Figure 7 and Figure 8).

Conclusion

Combining art and science is the most rewarding experience in dentistry. The case presented demonstrates how the Invisalign system combined with chairside composite veneers successfully treated a case with esthetic problems related to malalignment and discoloration of an old prolapsed restoration. In this case, the patient was overjoyed with the artistry of her new smile.

References

1. Nedwed V, Miethke RR. Motivation, acceptance and problems of Invisalign patients. *J Orofac Orthop.* 2005;66(2):162-173.
2. Meier B, Wiemer KB, Miethke RR. Invisalign--patient profiling. Analysis of a prospective survey. *J Orofac Orthop.* 2003;64(5):352-358.
3. Javaheri DS. Using technological advances to treat the crowded anterior dentition. *J Cosmetic Dent.* 2006;22(2):79-86.
4. Javaheri DS. Orthodontics, veneers, or both. Treatment planning the crowded anterior dentition. *Dent Today.* 2003;22(6):78-82.
5. Peyton JH. Direct restoration of anterior teeth: review of the clinical technique and case presentation. *Pract Proced Aesthet Dent.* 2002;14(3):203-212.
6. Zorba YO, Bayindir YZ, Barutcuoglu C. Direct laminate veneers with resin composites: two case reports with five-year follow-ups. *J Contemp Dent Pract.* 2010;11(4):E056-E062.
7. Trushkowsky R. Versatility of resin composite: esthetic considerations. *Compend Contin Educ Dent.* 2001;22(4):352-354, 356, 358 passim.
8. Fahl N Jr. A polychromatic composite layering approach for solving a complex Class IV/direct veneer-diastema combination: part I. *Pract Proced Aesthet Dent.* 2006;18(10):641-646.
9. Bauer J, Chiappelli F, Spackman S, et al. Evidence-based dentistry: fundamentals for the dentist. *J Calif Dent Assoc.* 2006;34(6):427-432.
10. Ishikawa-Nagai S, Yoshida A, Sakai M, et al. Clinical evaluation of perceptibility of color differences between natural teeth and all-ceramic crowns. *J Dent.* 2009;37(suppl 1):e57-e63.
11. Vanini L. Conservative composite restorations that mimic nature: a step-by-step anatomical stratification technique. *J Cosmetic Dent.* 2010;26(3):80-98.
12. Finlay SW. Stratification: An essential principle in understanding class IV composite restorations. Tips for accreditation case type IV. *J Cosmetic Dent.* 2012;28(1):32-34.
13. Vanini L. Anatomic stratification technique. Presented at: 26th Annual AACD Scientific Session; April 27, 2010; Grapevine, TX.

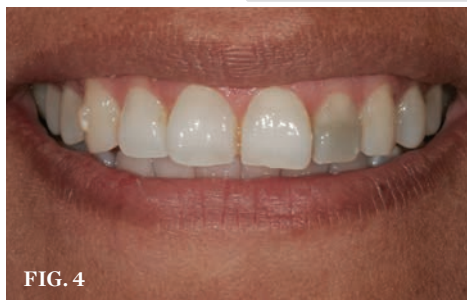

FIG. 4

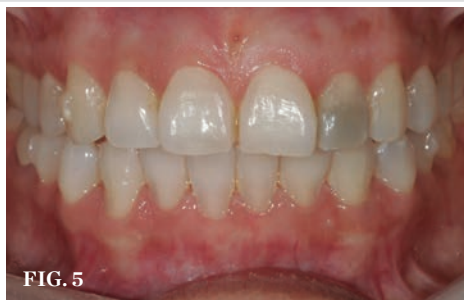

FIG. 5

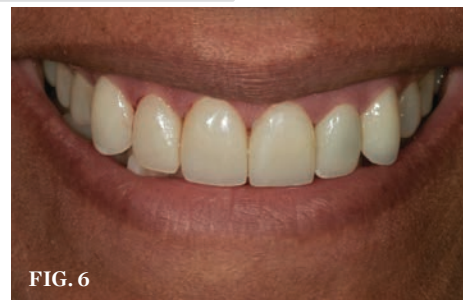

FIG. 6

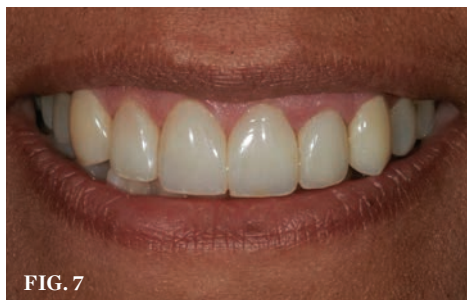

FIG. 7

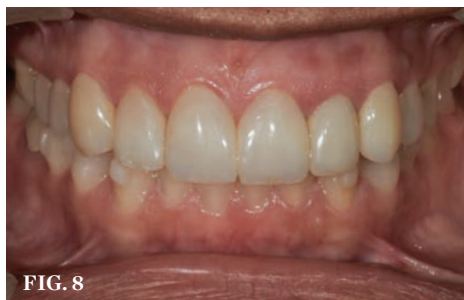

FIG. 8

(4.) Post-orthodontic treatment full smile. Note the improved alignment. (5.) Post-orthodontic treatment retracted frontal view. (6.) Full smile showing the mock-up temporaries. (7.) The post-restorative treatment full smile reflects a more pleasing smile. (8.) Post-restorative treatment retracted frontal view.